

SIGHT THREATENING OR LIFE THREATENING: A CASE REPORT OF OCULAR MANIFESTATION IN ACUTE LYMPHOBLASTIC LEUKAEMIA

Boon-Hooi Tan^{1*}, Jeyarine Monica Joan Royan¹, Khairy-Shamel Sonny-Teo¹

¹Department of Ophthalmology, School of Medical Sciences, Health Campus Universiti Sains Malaysia, 16150 Kubang Kerian, Kelantan, Malaysia.

**Corresponding Author:*

*Dr Boon Hooi Tan, Department of Ophthalmology, School of Medical Sciences, Health Campus Universiti Sains Malaysia, 16150 Kubang Kerian, Kelantan, Malaysia.
Tel: +6 09 767 6362, Fax: +6 09 765 3370, Email: boonhooi0920@yahoo.com*

<https://doi.org/10.32827/ijphcs.6.1.250>

ABSTRACT

Background: Acute lymphoblastic leukaemia (ALL) is the commonest childhood malignancy and ocular manifestations are uncommon in ALL. Patients may present with non-specific systemic symptoms which are overlooked and life threatening symptoms of leukostasis often present late. Here, we present a rare case of ALL where ocular symptoms preceded constitutional symptoms.

Materials and Methods: A case report.

Result: A 11-year-old girl presented with a syncopal attack during the fasting month to a primary health center. She was investigated at a tertiary center and diagnosed to have ALL. Further history revealed she had sudden painless severe reduced vision in the right for one month prior to this. Ocular assessment noted her right visual acuity was 5/60 and left visual acuity was 6/6. Her right fundus had a large subhyaloid haemorrhage over the macula and multiple large white-centered haemorrhages (Roth's spot); while the left fundus showed multiple large Roth's spots and some intraretinal haemorrhages. Chemotherapy was instituted after immunophenotyping was reported as precursor B-cell ALL. Ocular condition was managed conservatively. There was total resolution of the subhyaloid haemorrhage and retinal haemorrhages in both eyes and she regained full vision bilaterally while on induction therapy over 5 months.

Conclusion: Life threatening conditions such as ALL should be considered in children with sudden, painless, reduced vision and urgent ophthalmology assessment is important for early detection. Blurry vision could be the earliest symptom in ALL. Awareness on eye health must be emphasized in school by the educators for early detection of both sight and life threatening condition among children.

Keywords: lymphoblastic leukaemia, leukaemic ocular manifestation, subhyaloid haemorrhage.

1.0 Introduction

Acute lymphoblastic leukaemia (ALL) is an aggressive bone marrow malignancy where the normal haematopoietic cells are infiltrated and replaced by the early lymphoid precursor cells. This affects the normal haematopoietic differentiation, and there is decreased production of normal functional cells which leads to haematological anomalies such as thrombocytopenia, anemia, neutropenia, leukostasis and disseminated intravascular coagulation (Kanwar, 2019; Seiter, 2018). It is the commonest childhood malignancy both in developed and developing countries, leading before brain and central nervous system tumours (Seth & Singh, 2015; Ward, DeSantis, Robbins, Kohler, & Jemal, 2014). Mortality caused by this malignancy remains high. In general, paediatric malignancy is the second cause of death in children after accidents (Kochanek, Xu, Murphy, Miniño, & Kung, 2012).

In ALL, the leukaemic cells can infiltrate various organs, affecting both medullary and/or extramedullary systems. It can infiltrate the medullary system affecting lymph nodes, spleen, liver and bone. As a result, common presentations are fever, severe bony pain or osteopathy, lethargy, palpable lymphadenopathy, hepatosplenomegaly, bruising and rashes (Kanwar, 2019). For extramedullary extension, ALL commonly infiltrates to the testes, cerebrospinal fluid and uncommonly to the eye (Kim, Chang, & Sagong, 2010). Presentation of ALL is often vague in the early stages of the disease. Therefore, early diagnosis is difficult; moreover, patients often present late with complications at the late stage of disease (Jonsson, Sartain, Ducore, & Buchanan, 1990). We present a case report where ocular symptoms preceded the constitutional symptoms.

2.0 Materials and Methods

A case report.

3.0 Result

A 11-year-old girl presented with a syncopal episode during fasting month to the primary health center. She was referred to tertiary center for further workup due to leukocytosis. Her haemogram in primary care center showed total white cell count of $184 \times 10^9/l$, hemoglobin $6.5g/dl$ and platelet $96 \times 10^9/l$. Clinically, she was pale and afebrile with no jaundice, bruises, joint swelling, palpable lymphadenopathy or hepatomegaly. Further history revealed she had lethargy, but no significant history of bony pain, arthritis, fever, easy bruising, gum bleeding and abdominal distension. Otherwise, she gave history of sudden, painless, severe reduced vision in the right eye for a month prior to the syncopal attack and lethargy. Her peripheral blood film showed 80%-90% of blast cells while bone marrow aspiration confirmed blast cell >90% with immunophenotyping demonstrated precursor B-cell ALL.

On ocular assessment, her right visual acuity was 5/60 and left visual acuity was 6/6. There was no proptosis and no relative afferent pupillary defect. Her extraocular movements were full. Both anterior segments were normal. The right fundus had a large subhyaloid haemorrhage over the macula and multiple large white-centred haemorrhages (Roth's spots); while the left fundus showed multiple large Roth's spots and some intraretinal haemorrhages over the posterior pole and the peripheral retina (Figure 1). Both optic discs were normal and there was no vitritis or exudative retinal detachment bilaterally.

Chemotherapy was instituted following the Berlin-Frankfurt-Muenster (BFM-95) protocol with intrathecal Methotrexate after the immunophenotyping was confirmed with to be precursor B-cell ALL. Her ocular condition was managed conservatively. There was total resolution of the macular subhyaloid haemorrhage and retinal haemorrhages in both eyes, and she resumed her full vision after 5 months duration (Figure 2). She is currently in remission state under close follow up for 2 years after chemotherapy was completed.

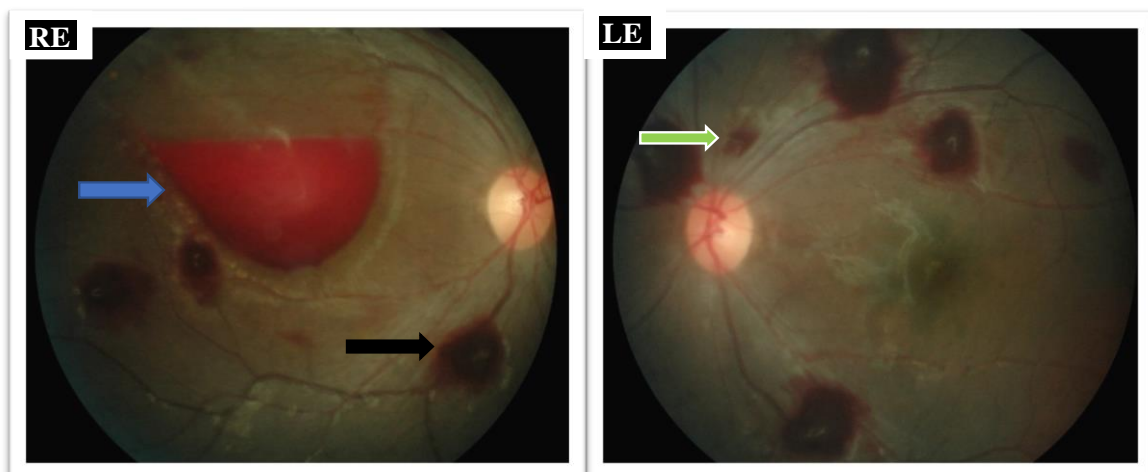


Figure 1: Right and left fundus photos at first presentation. Right fundus showing subhyaloid haemorrhage over the macula (blue arrow) and multiple Roth's spots (black arrow) over posterior segment. Left fundus showing multiple Roth's spots, intraretinal haemorrhages (green arrow) and good foveal reflex. Both fundus photos showing clear medium with no vitritis and normal optic disc.

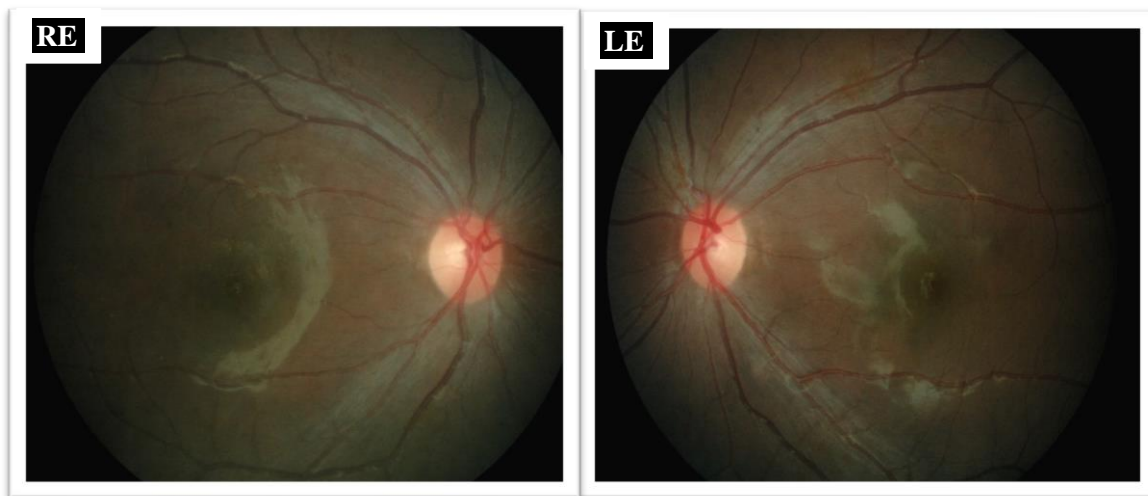


Figure 2: Fundus photos of both eyes showing normal ocular findings with no retinal haemorrhage at 5 months review.

4.0 Discussion

Ocular manifestations in leukaemia can vary from asymptomatic to sight threatening. In acute leukaemia, ocular manifestation can be due to direct infiltration by the leukaemic cells or secondary to haematological anomalies (Sharma, Grewal, Gupta, & Murray, 2004). Direct infiltration affects ocular structure such as orbital adnexal, iris, choroid and optic nerve (Mateo et al., 2011). Orbital infiltration is more common in ALL (Cardone, Yen, Chévez-Barrios, Foroozan, & Yen, 2006). Both proptosis and diplopia are common presentations. Optic nerve involvement is an ocular emergency that requires prompt treatment with chemotherapy, intrathecal Methotrexate and cranial irradiation as to cover treatment for CNS extension and to save vision (Kaikov, 1996; Mayo, Carter, & McKinnon, 2002). Papilloedema, optic perineuritis and optic neuritis are the presenting features of optic nerve infiltration.

Haematological anomalies result from bone marrow infiltration, causing hyperviscosity, leading to venous stasis. Since retinal vasculature is the usual site of involvement, as many as 70% of all leukaemic patients showed retinal changes during illness (Alemayehu, Shamebo, Bedri, & Mengistu, 1996; Reddy, Jackson, & Menon, 2003). Venous tortuosity and engorgement were appreciated in the early manifestation of the disease (Ballantyne & Michaelson, 1970). In leukaemic retinopathy, the retinal haemorrhages can involve all retinal layers especially over the posterior pole, manifesting as flamed shape haemorrhages, intraretinal haemorrhage, preretinal haemorrhage and vitreous haemorrhage (Sharma, Grewal, Gupta, & Murray, 2004). Roth's spots are non-specific as it can also, be seen in conditions with anoxia such as severe anaemia, prolonged intubation, hypertensive retinopathy and pre-eclampsia (Ling & James, 1998). There is usually no treatment needed for retinal haemorrhage as it is self-limiting unless it threatens the central vision. There are a few treatment options available for large macular subhyaloid or preretinal haemorrhages to hasten the process of

absorption to prevent long term effects of haemoglobin and iron over the macula which may contribute to pigmentary maculopathy causing permanent vision damage (Karolien De Maeyer, Rita Van Ginderdeuren, Laurence Postelmans, Peter Stalmans, & Joachim Van Calster, 2007). These include pars plana vitrectomy, neodymium-doped yttrium aluminium garnet (Nd:YAG) laser hyaloidotomy, intravitreal anti vascular endothelial growth factor (VEGF) (K. De Maeyer, R. Van Ginderdeuren, L. Postelmans, P. Stalmans, & J. Van Calster, 2007; Fernández, Navarro, & Castaño, 2012; Kirwan & Cahill, 2011; Noorlaila, Zunaina, & Raja-Azmi, 2016). In this case, the subhyaloid haemorrhage was managed conservatively.

Ocular manifestations in children is less common compared to adult ALL and in comparison, ALL has lesser ocular involvement than acute myeloidblastic leukaemia (AML) (Kincaid & Green, 1983; Russo et al., 2008). The prognosis in patients with ocular involvement is poor compared to those without ocular involvement as the rate of CNS relapse is higher and thus associated with a lower survival rate (Ohkoshi & Tsiaras, 1992).

In our case, this child was having ocular symptom of one month which preceded the symptoms of lethargy and syncopal attack. However, she did not seek any medical attention for her sudden reduced vision and was only brought to medical attention a month later by parents due to the syncopal attack. Fundus assessment via fundus photography operated by trained medical personnel in primary health care clinics may be helpful to screen for fundus pathology when patients present with eye symptom and non-specific constitutional symptoms. Given that children spend almost 6 hours at school, health education should start as early as possible to bring awareness on taking the responsibility of one's own health. Yearly national eye screening programs can be beneficial in detecting common treatable ocular problems such as refractive errors and amblyopia and to screen for life threatening condition associated with ocular manifestation.

5.0 Conclusion and recommendation

High index of suspicious for life threatening condition such as ALL should be considered in children with sudden painless reduced vision and urgent ophthalmology referral is important for early detection. Blurry vision could be the earliest symptom in ALL. Awareness on eye health must be emphasized in school by the educators for early detection of both sight and life threatening condition among children.

Acknowledgement

Case report above is acknowledge and granted approval by patient, contributing authors and hospital.

Declaration

Author(s) declare that there is no financial interest in the above case.

References

- Alemayehu, W., Shamebo, M., Bedri, A., & Mengistu, Z. (1996). Ocular manifestations of leukaemia in Ethiopians. *Ethiopian medical journal*, 34(4), 217-224.
- Ballantyne, A. J., & Michaelson, I. C. (1970). *Textbook of the Fundus of the Eye*: Churchill Livingstone.
- Cardone, S., Yen, M. T., Chévez-Barrios, P., Foroozan, R., & Yen, K. G. (2006). Recurrent acute lymphoblastic leukemia presenting in the lacrimal gland. *Ophthalmic Plastic & Reconstructive Surgery*, 22(1), 56-57.
- De Maeyer, K., Van Ginderdeuren, R., Postelmans, L., Stalmans, P., & Van Calster, J. (2007). Sub-inner limiting membrane haemorrhage: causes and treatment with vitrectomy. *British Journal of Ophthalmology*, 91(7), 869-872.
- Fernández, M. G., Navarro, J. C., & Castaño, C. G. (2012). Long-term evolution of Valsalva retinopathy: a case series. *Journal of medical case reports*, 6(1), 346.
- Jonsson, O. G., Sartain, P., Ducore, J. M., & Buchanan, G. R. (1990). Bone pain as an initial symptom of childhood acute lymphoblastic leukemia: association with nearly normal hematologic indexes. *The Journal of pediatrics*, 117(2), 233-237.
- Kaikov, Y. (1996). Optic nerve head infiltration in acute leukemia in children: an indication for emergency optic nerve radiation therapy. *Medical and Pediatric Oncology: The Official Journal of SIOP—International Society of Pediatric Oncology (Société Internationale d'Oncologie Pédiatrique)*, 26(2), 101-104.
- Kanwar, V. S. (2019). Pediatric Acute Lymphoblastic Leukaemia. Retrieved from <https://emedicine.medscape.com/article/990113-overview>
- Kim, J., Chang, W., & Sagong, M. (2010). Bilateral serous retinal detachment as a presenting sign of acute lymphoblastic leukemia. *Korean Journal of Ophthalmology*, 24(4), 245-248.
- Kincaid, M. C., & Green, W. R. (1983). Ocular and orbital involvement in leukemia. *Survey of ophthalmology*, 27(4), 211-232.
- Kirwan, R., & Cahill, M. (2011). Nd: YAG laser hyaloidotomy for Valsalva pre-macular haemorrhage. *Irish journal of medical science*, 180(3), 749-752.
- Kochanek, K., Xu, J., Murphy, S. L., Miniño, A. M., & Kung, H.-C. (2012). Deaths: Final Data for 2009. *National Vital Statistics Reports*; Vol. 60, no. 3.

- Ling, R., & James, B. (1998). White-centred retinal haemorrhages (Roth spots). *Postgraduate medical journal*, 74(876), 581-582.
- Mateo, J., Ascaso, F. J., Núñez, E., Peiro, C., González, G., & Cristóbal, J. A. (2011). Ophthalmological manifestations in acute lymphoblastic leukemia. In *Novel Aspects in Acute Lymphoblastic Leukemia: InTech*.
- Mayo, G. L., Carter, J. E., & McKinnon, S. J. (2002). Bilateral optic disk edema and blindness as initial presentation of acute lymphocytic leukemia. *American journal of ophthalmology*, 134(1), 141-142.
- Noorlaila, B., Zunaina, E., & Raja-Azmi, M.-N. (2016). Successful Resolution of Preretinal Haemorrhage with Intravitreal Ranibizumab. *Case reports in ophthalmological medicine*, 2016.
- Ohkoshi, K., & Tsiaras, W. (1992). Prognostic importance of ophthalmic manifestations in childhood leukaemia. *British Journal of Ophthalmology*, 76(11), 651-655.
- Reddy, S., Jackson, N., & Menon, B. (2003). Ocular involvement in leukemia—a study of 288 cases. *Ophthalmologica*, 217(6), 441-445.
- Russo, V., Scott, I. U., Querques, G., Stella, A., Barone, A., & Delle Noci, N. (2008). Orbital and Ocular Manifestations of Acute Childhood Leukemia: Clinical and Statistical Analysis of 180 Patients. *European journal of ophthalmology*, 18(4), 619-623.
doi:10.1177/112067210801800420
- Seiter, K. (2018, July 17, 2018). Acute Lymphoblastic Leukaemia. Retrieved from <https://emedicine.medscape.com/article/207631-overview>
- Seth, R., & Singh, A. (2015). Leukemias in children. *The Indian Journal of Pediatrics*, 82(9), 817-824.
- Sharma, T., Grewal, J., Gupta, S., & Murray, P. (2004). Ophthalmic manifestations of acute leukaemias: the ophthalmologist's role. *Eye*, 18(7), 663.
- Ward, E., DeSantis, C., Robbins, A., Kohler, B., & Jemal, A. (2014). Childhood and adolescent cancer statistics, 2014. *CA: a cancer journal for clinicians*, 64(2), 83-103.